

ORIGINAL ARTICLE

Combination radiofrequency and diode laser for treatment of facial rhytides and skin laxity

SEEMA N. DOSHI & TINA S. ALSTER

Washington Institute of Dermatologic Laser Surgery, Washington, DC, USA

Abstract

Purpose. As the demand for noninvasive procedures to address cutaneous aging issues has increased, novel nonablative lasers and radiofrequency (RF) devices have recently emerged. The objective of this study was to evaluate the safety and efficacy of a combination RF/diode laser device designed to target both skin laxity and facial rhytides.

Materials and methods. Twenty patients (skin phototypes I–III) with mild to moderate rhytides and skin laxity received three treatments at 3-week intervals with a combined radiofrequency and diode laser system (Polaris WRTM, Syneron Medical Ltd, Israel). Clinical improvement was determined through masked assessments by the treating investigator and two independent assessors after each treatment session, and at 3 and 6 months after the final treatment using a quartile grading scale (1 < 25%; 2 = 25–50%; 3 = 51–75%; 4 > 75% improvement). Patient satisfaction surveys were also obtained at end-study.

Results. Modest improvement in facial rhytides was observed in the majority of patients as evidenced by investigator and independent assessor evaluations. Patient satisfaction surveys reflected the clinical improvements observed. Side effects were mild and limited to transient erythema and edema. No scarring or pigmentary alteration was seen.

Conclusions. The Polaris WRTM, which sequentially delivers radiofrequency and diode laser energy, is safe and effective for treatment of mild to moderate facial rhytides and skin laxity. Multiple treatment sessions and laser passes were well tolerated by patients due to the minimization of individual optical and radiofrequency energies used.

Key words: Laser, nonablative, photodamage, radiofrequency, rhytides, skin laxity

Introduction

Nonablative dermal remodeling has gained tremendous popularity among patients and practitioners, offering a low incidence of adverse effects and modest improvement in the various signs of cutaneous photoaging, including rhytides, dyschromias and telangiectasias. The evolving list of nonablative laser and light systems used for skin rejuvenation includes pulsed dye (585, 595 nm), intense pulsed light or IPL (500–1200 nm), Nd:YAG (1064, 1320 nm), diode (910, 1450 nm), and Er:Glass (1540 nm) lasers (1–10). Despite specificity for different dermal chromophores, the end result of the targeted energy is stimulation of fibroblasts and new collagen formation. Radiofrequency technology is another promising addition to the nonablative skin rejuvenation armamentarium. Unlike traditional laser systems that generate heat by targeting specific chromophores, radiofrequency technology generates heat as a result of tissue impedance and is dependent

on the electrical properties of tissue (11,12). Controlled thermal injury has been shown to effect a conformational change in the structure and length of collagen and may also induce fibroblast response for long-term collagen remodeling (13). Interest in utilizing radiofrequency energy to enhance deep tissue tightening and thus improve skin laxity has grown, as radiofrequency energy has been shown in multiple studies to tighten tissue, producing a noticeable skin lifting effect (12,14–16).

A novel device, Polaris WRTM (Syneron Medical Ltd, Israel), which combines radiofrequency and diode laser energies (termed electro-optical synergy or ELOSTM) has been developed in an attempt to address both facial rhytides and skin laxity. This device delivers radiofrequency energy ranging 10 J/cm³ to 100 J/cm³ and optical energy (910 nm diode) ranging 10 J/cm² to 50 J/cm² in a sequential manner through a unique bipolar electrode tip. Thermoelectric cooling at 5°C provides epidermal protection throughout the pulse sequence. This prospective

Correspondence: Tina S. Alster, M.D., Washington Institute of Dermatologic Laser Surgery, 2311 M Street, N.W., Suite 200, Washington, D.C. 20037, USA. Fax: +1-202-785-8858. E-mail: talster@skinlaser.com

(Received 3 January 2005; accepted 8 March 2005)

study was initiated to evaluate the efficacy and safety of Polaris WRTM in the treatment of mild to moderate facial rhytides and skin laxity.

Materials and methods

Twenty females (mean age 52.5 years, skin phototypes I–III) with mild-moderate facial rhytides and cheek and/or neck laxity were included in the study, in accordance with the Essex Institutional Review Board (Lebanon, NJ). Exclusion criteria included known photosensitivity, pregnancy, diabetes, tanned skin, use of isotretinoin in the six months preceding treatment, use of pacemakers or internal defibrillators, and concurrent treatments with any other aesthetic modality. Topical anesthetic cream (LMX-5, Ferndale Laboratories, Inc., Ferndale, MI) was applied under plastic wrap to the entire face for 60 minutes and then completely removed with water-soaked gauze prior to the procedure. An aqueous conducting gel was applied to the skin and three consecutive nonoverlapping passes using the Polaris WRTM device (Syneron Medical Ltd, Israel) were delivered to the entire face. Treatment parameters (optical energy 32–40 J/cm², mean 36.4 J/cm²; radiofrequency 50–85 J/cm³, mean 67.4 J/cm³) were adjusted to produce immediate mild erythema and edema of the skin without signs of epidermal damage (vesiculation). Radiofrequency energy was lowered by 10% for treatment of the forehead and periocular regions. At each subsequent treatment session, the energies were increased by 10% as indicated by the patient's immediate clinical response and pain tolerance. An additional (fourth) pass was performed over select areas including nasolabial, mesolabial, and lateral canthal rhytides as indicated by lesional severity and tissue response. Three treatments were performed at 3-week intervals by the same operator (SD).

Clinical photographs of treatment areas using identical camera settings, lighting, and patient positioning were obtained at baseline, at each 3-week follow-up visit, and at 3 and 6 months after the final treatment session. At each patient visit, the degree of clinical improvement in 4 separate treatment areas (nasolabial/mesolabial folds, perioral region, periocular area, cheek laxity) was assessed by the investigator and an independent assessor using a quartile grading scale (0=no change from

baseline; 1 < 25% improvement; 2 = 26–50% improvement; 3 = 51–75% improvement; 4 > 75% improvement). At the immediate conclusion of the study and at 3 months and 6 months after the study, two independent assessors blinded to the treatment protocol and subjects graded, on the same quartile scale, clinical improvement from baseline. Patients completed satisfaction surveys at the conclusion of the study and kept a daily diary of adverse events after each treatment.

Results

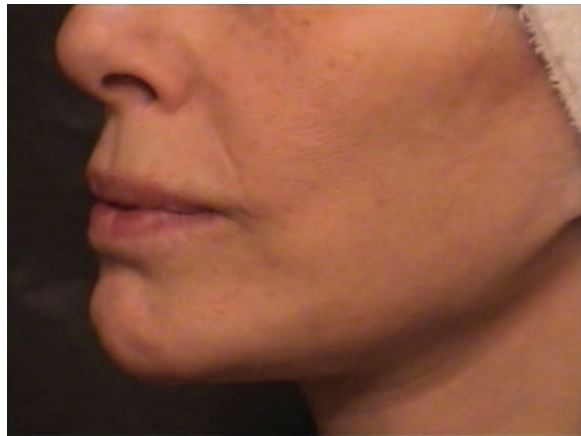Clinical improvement of nasolabial and mesolabial rhytides was observed at 3-week, 6-week, 9-week, and 3-month post-treatment evaluations with mean clinical scores of 1.15, 1.30, 1.33, and 2.00, respectively. At the final 6-month assessment, all patients exhibited improvement with a mean clinical score of 1.63 (Table I, Figure 1). Periocular rhytides were also significantly improved with scores of 1.30, 1.30, 1.33, and 1.62 at each of the 4 assessment periods (Figure 2). Slightly lower mean improvement scores of 1.00, 1.20, 1.33, and 1.38 at the 3-week, 6-week, 9-week, and 3-month follow-up visits were seen in the perioral region. Clinical improvement in both areas was again noted to be slightly reduced at 6 months, with mean clinical improvement scores of 1.27 for perioral rhytides and 1.33 for periorbital rhytides. Skin laxity in the cheek and jowl regions was improved with mean clinical improvement scores of 1.15, 1.40, 1.44, and 1.85 at 3 weeks, 6 weeks, 9 weeks, and 3 months post-treatment. Interestingly, continued improvement of skin laxity was noted 6 months following the series of treatments, with a mean score of 2.0 (Figure 3). No significant differences were seen in clinical improvement scores between masked assessors' evaluations and the investigator assessments.

Patient assessments of clinical improvement also paralleled the investigator's and independent observers' assessments with mean clinical scores at 9 weeks of 1.63 for periocular rhytides, 1.50 for perioral rhytides, 1.50 for nasolabial/mesolabial rhytides, and 1.69 for overall skin laxity. Three- and six-month scores were 1.77 and 1.80 in the periorbital area, 1.31 and 1.10 in the perioral area, 1.77 and 1.63 in the nasolabial fold area, and 1.46 and 1.36 in skin laxity. At the 9-week, 3-month, and

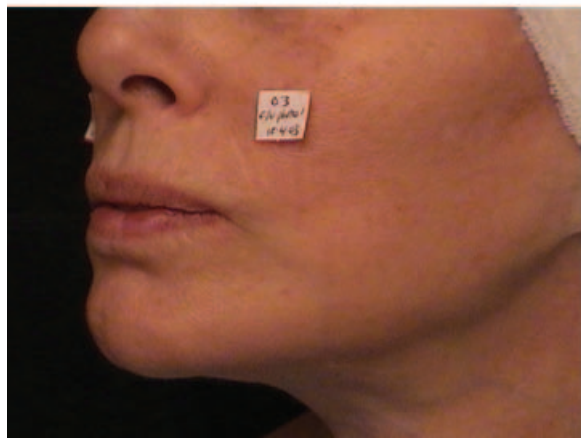Table I. Clinical improvement scores.

Location	3 weeks	6 weeks	9 weeks	3 months	6 months
Nasolabial/mesolabial	1.15	1.3	1.33	2.0	1.63
Periocular	1.3	1.3	1.33	1.62	1.33
Perioral	1.0	1.2	1.3	1.38	1.27
Cheek laxity	1.15	1.4	1.44	1.85	2.0

Grading scale: 0=no change; 1 < 25% improvement; 2=25–50% improvement; 3=51–75% improvement; 4 > 75% improvement from baseline.



(A)



(B)

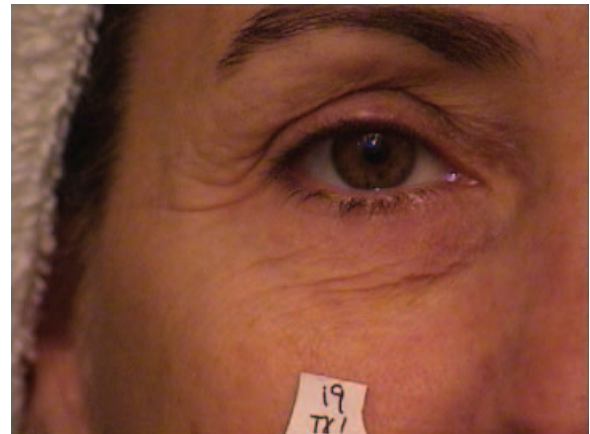
Figure 1. Nasolabial folds before (A) and 3 months after third RF/diode treatment (B). Clinical improvement score=2.

6-month follow-up visits, 93%, 86%, and 81% of patients, respectively, reported satisfaction with their results.

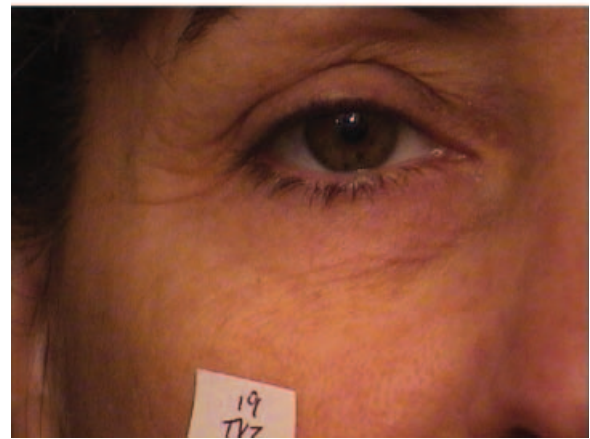The treatment was generally well tolerated, with 2 patients (10%) reporting no discomfort, 16 patients (80%) experiencing mild pain, and 2 patients (10%) experiencing moderate pain limited to the forehead and periorbital areas. Transient post-treatment erythema was universal to the procedure and 80% of patients experienced edema of 24 hours duration. Vesiculation was reported in 10% of patients (2 out of 60 treatment sessions=3% total), which resolved without sequelae within 5 days. No pigmentary alteration or scarring was seen in any patient.

Discussion

The data reported herein demonstrate that a combination diode laser and radiofrequency device offers a safe and effective nonablative method to improve tissue laxity and facial rhytides. Electro-optical synergy (ELOSTM) technology was first demonstrated with the Aurora SRTM device (Syneron Medical Ltd, Israel) in which intense pulsed light and radiofrequency energies are simultaneously



(A)



(B)

Figure 2. Periocular rhytides before (A) and 3 months after third RF/diode treatment (B). Clinical improvement score=2.

applied to the skin. The optical energy preheats the target tissue, attracting the longer application of radiofrequency towards the target structure due to lowered impedance at the target (13). The combination IPL/RF device has been shown to be efficacious in skin rejuvenation, producing noticeable improvement in erythema, telangiectasia, hyperpigmentation, lentigines, and fine lines (17). Unwanted dark and light hair has also been significantly reduced with the combination RF/IPL system, presumably by drawing optical energy to the nonpigmented hair via non-selective radiofrequency (18).

The Polaris WRTM system used in this study delivers approximately 70 ms of RF energy and delayed diode energy (near the end of the radiofrequency pulse). This sequence permits heating to a maximal dermal depth of 2 mm. The geometry of bipolar electrodes creates controlled thermal injury to the deep dermis at minimal individual optical and radiofrequency energies, thereby limiting adverse effects of tissue overheating.

The majority of patients demonstrated improvement of facial rhytides and skin laxity after a series of combination RF/diode laser treatments. Progressive improvement was observed after a series of treatments using multiple successive laser passes. The

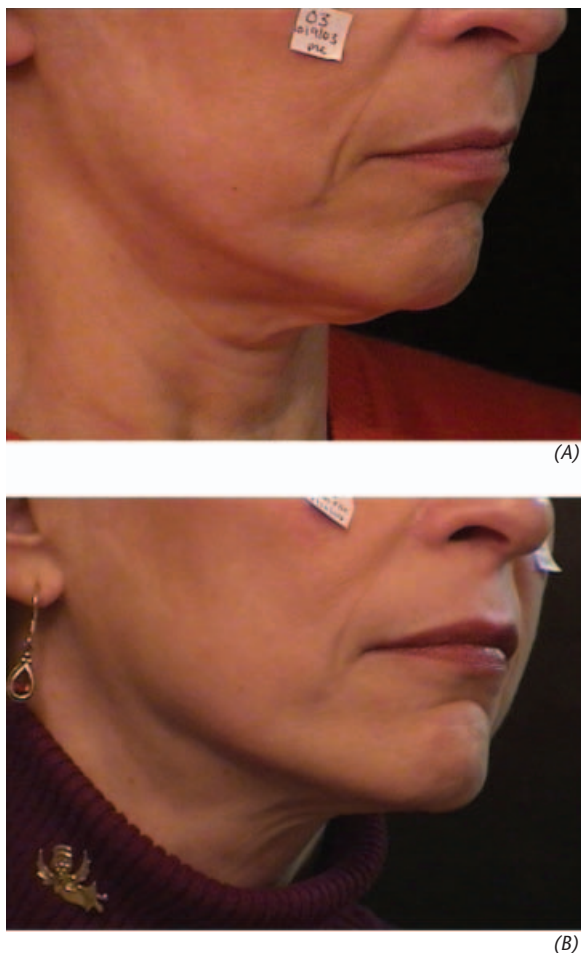

Figure 3. Cheek laxity before (A) and 6 months after third RF/diode treatment (B). Clinical improvement score=3.

clinical results were maintained for the 6-month follow-up period. Even further improvement of cheek laxity was noted at the final evaluation, indicating prolonged progressive tissue tightening results from treatment. Recent studies with another radiofrequency device (ThermaCool TC, Thermage, Inc., Hayward, CA) have suggested that multiple low fluence passes increases the amount of collagen contraction (19) and that multiple treatment sessions may lead to additional clinical efficacy (20). Multiple passes and treatment sessions are clinically feasible with the Polaris WRTM used in this study due to the speed and ease at which the pulses can be delivered. Additionally, patients are able to tolerate the multiple pass protocol without significant discomfort or increased risk of side effects.

Conclusions

The combination of conducted radiofrequency and optical energies, as delivered by the Polaris WRTM device, demonstrated measurable improvement in both facial rhytides and skin laxity. Pulses of radiofrequency energy in the range of 50–85 J/cm³ applied to the skin in conjunction with diode laser

energy ranging 32 J/cm² to 40 J/cm² were well tolerated and associated with nominal side effects. This novel device offers patients with mild to moderate rhytides and skin laxity an appealing alternative to more invasive surgical interventions and adds to our growing list of nonablative skin treatment tools. Further studies are warranted to enhance our understanding of this device and to optimize treatment parameters.

References

1. Bjerring P, Clement M, Heikendorff L, Egevis H, Kiernan M. Selective non-ablative wrinkle reduction by laser. *J Cutan Laser Ther.* 2000;2:9–15.
2. Rostan EF, Bowes LE, Iyer S, Fitzpatrick RE. A double-blind, side-by-side comparison study of low fluence long pulse dye laser to coolant treatment for wrinkling of the cheeks. *J Cosmet Laser Ther.* 2001;3:129–36.
3. Tanghetti EA, Sherr EA, Alvarado SL. Multipass treatment of photodamage using the pulse dye laser. *Dermatol Surg.* 2003;29:686–91.
4. Goldberg DJ, Cutler KB. Nonablative treatment of rhytids with intense pulsed light. *Lasers Surg Med.* 2000;26:196–200.
5. Bitter PH Jr. Nonablative photorejuvenation of photodamaged skin using serial, full-face intense pulsed-light treatments. *Dermatol Surg.* 2000;26:835–43.
6. Goldberg DJ, Silapunt S. Histologic evaluation of a Q-switched Nd:YAG laser in the nonablative treatment of wrinkles. *Dermatol Surg.* 2001;21:744–6.
7. Fatemi A, Weiss MA, Weiss RA. Short term histologic effects of nonablative resurfacing: Results with a dynamically cooled millisecond-domain 1320 nm Nd:YAG laser. *Dermatol Surg.* 2002;28:172–6.
8. Muccini JA, O'Donnell FE, Fuller T, Reinisch L. Laser treatment of solar elastosis with epithelial preservation. *Lasers Surg Med.* 1998;23:121–7.
9. Tanzi EL, Williams CM, Alster TS. Treatment of facial rhytides with a nonablative 1450 nm diode laser: A controlled clinical and histologic study. *Dermatol Surg.* 2003;29:124–8.
10. Lupton JR, Williams CM, Alster TS. Nonablative laser skin resurfacing using a 1540 nm erbium glass laser: A clinical and histologic analysis. *Dermatol Surg.* 2002;28:833–5.
11. Ruiz-Esparza J, Gomez JB. The medical face lift: a noninvasive, nonsurgical approach to tissue tightening in facial skin using nonablative radiofrequency. *Dermatol Surg.* 2003;29:325–32.
12. Sadick NS, Makino Y. Selective electro-thermolysis in aesthetic medicine: a review. *Lasers Surg Med.* 2004;34:91–7.
13. Ross EV, Naseef M, Skrobul JM, et al. In vivo dermal collagen shrinkage and remodeling following CO₂ laser resurfacing. *Lasers Surg Med.* 1996;19:38.
14. Hsu TS, Kaminer MS. The use of nonablative radiofrequency technology to tighten the lower face and neck. *Semin Cutan Med Surg.* 2003;22:115–23.
15. Fitzpatrick R, Geronemus R, Goldberg D, Kaminer M, Kilmer S, Ruis-Esparza J. Multicenter study of noninvasive radiofrequency for periorbital tissue tightening. *Lasers Surg Med.* 2003;33:232–42.
16. Alster TS, Tanzi E. Improvement of neck and cheek laxity with a nonablative radiofrequency device: a lifting experience. *Dermatol Surg.* 2004;30:503–07.
17. Bitter P Jr, Mulholland S. Report of a new technique for enhanced non-invasive skin rejuvenation using a dual-mode pulsed light and radiofrequency energy source: Selective radiothermolysis. *J Cosmet Dermatol.* 2002;1:142–3.

18. Sadick NS, Shaoul J. Hair removal using a combination of conducted radiofrequency and optical energies—an 18-month follow-up. *J Cosmet Laser Ther.* 2004;6(1):21–6.
19. Zelickson BD, Kist D, Bernstein E, Brown DB, Ksenzenko S, Burns J, et al. Histological and ultrastructural evaluation of the effects of a radiofrequency-based nonablative dermal remodeling device: a pilot study. *Arch Dermatol.* 2004;104:204–09.
20. Fritz M, Counters JT, Zelickson BD. Radiofrequency treatment for middle and lower face laxity. *Arch Facial Plastic Surg.* 2004;6(6):370–3.